

Using Stratus OCT to Track Macula Thickness Changes in the Left Eye Without Surgical Assistance

By Robert Raden, M.D.
Elman Retina Group, Baltimore

The patient

A 66-year-old man presented with decreased vision in his left eye for 1 month. His visual acuity for the left eye was 20/60 and he denied any history of ocular trauma or surgery. The clinical exam revealed a dull reflex, and the fluorescein angiogram and fundus photo were normal.

The Stratus OCT diagnosis

Optical coherence tomography (OCT) showed evidence of traction and thickening of the central macula from a taut posterior hyaloid (vitreomacular traction syndrome). Based on the Stratus OCT, the retinal thickness was 323 μ m in the center field. A crosshair image showed the vitreous pulling up on the central fovea.

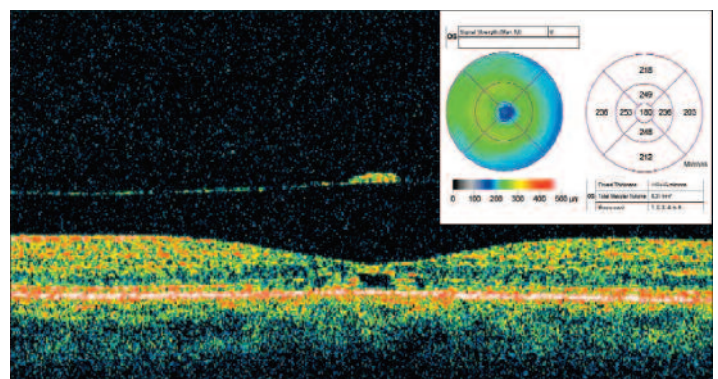
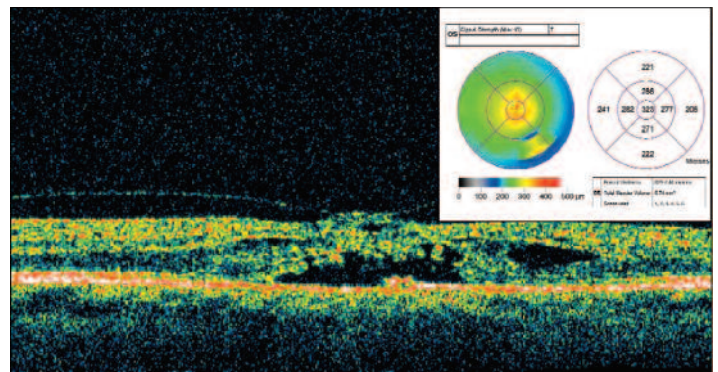
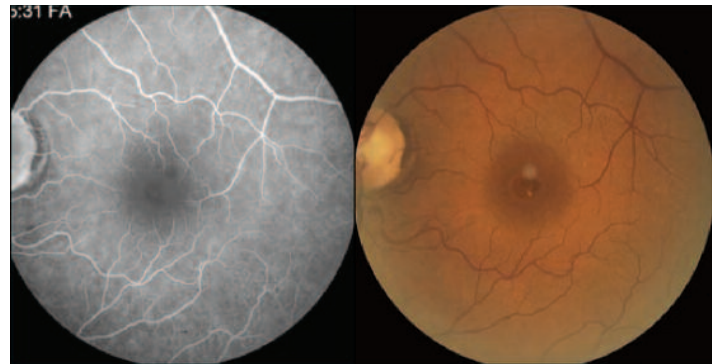
Outcome

Because there was no open hole, I decided to observe the situation for a short time. After 2 months, the patient began to have spontaneous improvement in his vision, eventually improving from 20/60 to 20/20.

Conclusion

A remarkable detachment of the vitreous and relief of traction had occurred. The Stratus OCT revealed a normal thickness of 180 μ m; and the crosshair image of the macula showed flattening of the fovea with several tiny cystic pockets remaining. Most interesting was a small operculum of lamellar retinal tissue floating above the fovea.

Because of the detail provided early on by the Stratus OCT, I was comfortable following the patient for a short time, hoping for a spontaneous detachment of the vitreous from the fovea. The amount of traction was subclinical, even with careful contact lens exam. The Stratus OCT truly provided the diagnosis and allowed for careful, conservative management.



Note: The author has no financial interest in this material.